

## Aorto-oesophageal Fistula from Miliary Tuberculosis: A Rare Cause of Massive Haematemesis

### Dear Editor,

Aorto-oesophageal fistula (AEF) is a rare surgical emergency that is often lethal. Primary causes described include thoracic aortic aneurysm<sup>1</sup> and carcinoma of the oesophagus.<sup>2</sup> Secondary causes include foreign body ingestion<sup>3</sup> such as chicken and fish bones, surgical instrumentation, and procedures such as oesophageal biopsy,<sup>4</sup> and erosion from aortic bypass grafts.<sup>5</sup> In this case report, we describe a patient with AEF who presented with massive haematemesis from an oesophageal lesion found on endoscopy.

### Case Report

A 46-year-old Filipino female presented to the emergency department in shock after 2 episodes of haematemesis at home. She did not have a history of foreign body ingestion. Investigations showed anaemia with a haemoglobin level of 6.4 mg/dL, but electrolytes and liver function tests were otherwise normal. A chest x-ray done was initially thought to be normal, but later was reported as having bilateral interstitial markings suggestive of possible infective change (Fig. 1).

She was brought to the endoscopy centre for emergency oesophagogastroduodenoscopy (EGD), which demonstrated large amounts of fresh blood and clots in the stomach. The oesophagus was not visualised well. During the procedure, the patient had cardiovascular collapse and developed pulseless electrical activity. She was therefore transferred

to the operating theatre for emergency surgery. At this point, it was assumed that the source of the bleeding was from the stomach or duodenum secondary to peptic ulcer disease.

At laparotomy, a gastrostomy was performed and bleeding was found to be coming from above the cardio-oesophageal junction. An on-table EGD was performed, and an actively spurting vessel was seen at 25 cm from the incisors. Attempts were made at endoscopic haemostasis with haemoclips and adrenaline injection without success. Insertion of a Sengstaken–Blakemore tube for tamponade also failed to arrest the bleeding. An intraoperative angiogram was performed on-table to identify the bleeding vessel, with a view to angio-embolisation. Unfortunately, due to poor cardiac output, the fistula was not well visualised except for a small area of abnormal vasculature near the area of haemorrhage. The impression then was a vascular malformation causing massive haemorrhage.

The patient had multiple episodes of cardiovascular collapse intraoperatively despite massive blood product transfusions and this led to her eventual demise.

At the postmortem examination, she was found to have disseminated miliary tuberculosis involving multiple organs including the kidneys and the lungs. The cause of AEF was found to be a necrotic nodule interposed between the aorta and oesophagus measuring about 3 cm in diameter. Several other small lymph nodes with miliary tuberculosis were seen in the region of the nodule. The pleural surfaces of both lungs were also heavily studded with miliary nodules.

### Discussion

AEF are relatively rare, but almost universally fatal. There are few reported cases of survival. The patient usually has a history of recent foreign body ingestion or recent interventional procedures such as an oesophageal biopsy. The most common causes are thoracic aneurysms (51%), foreign body ingestion (19%), and oesophageal carcinoma.<sup>6</sup>

Tuberculous disease of the gastrointestinal (GI) tract can present in different ways. Other than bleeding, it may also present as intestinal obstruction.<sup>7</sup> There are multiple published reports of tuberculosis-associated GI bleeding. Depending on the aetiology and location of the pathology, the patient may present with upper or lower GI bleeding.

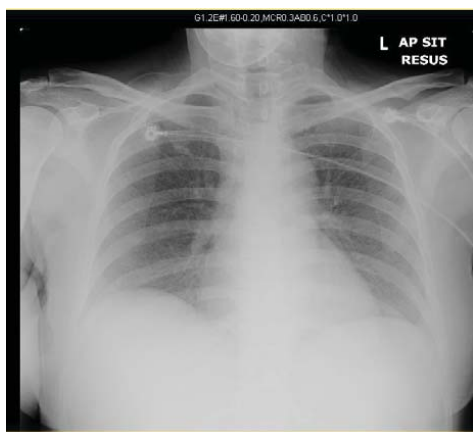


Fig. 1. Chest x-ray performed at admission.

Tuberculosis may affect the organs of the GI tract directly;<sup>8</sup> it may also result in pseudoaneurysms or mycotic aneurysms of adjacent vessels with subsequent involvement of the GI tract, such as a jejunal artery pseudoaneurysm involving the jejunum;<sup>9</sup> tuberculous mediastinitis can erode into the oesophagus and aorta, causing haemorrhage into the oesophagus presenting as upper GI bleeding. In the case described here, tuberculous mediastinitis resulted in erosion into both the oesophagus and aorta with formation of an AEF.

Tuberculous AEF is uncommon. Fistulae secondary to tuberculous esophagitis have been reported,<sup>10</sup> but only 1 case secondary to tuberculous mediastinitis has been described in literature by Lee et al.<sup>11</sup> In that case report, the patient survived the initial surgery having undergone an Ivor–Lewis procedure, but succumbed to pulmonary complications about 2 months postoperatively.

Here, we describe a case of primary AEF as a complication of mediastinal tuberculosis. The patient had miliary tuberculosis that was not diagnosed at initial presentation. She presented with massive upper bleeding GI tract and haemorrhagic shock. The nodule of mycobacterium infection presumably eroded through the aorta and the oesophagus, resulting in a fistula and massive haemorrhage.

The management for AEF has been previously described.<sup>12,13</sup> Different methods have been used, including aortic graft replacement and esophagectomy with both primary and delayed oesophago-gastro anastomosis.<sup>14</sup> For fistulae secondary to thoracic aneurysms, aortic stent grafting for initial haemostasis, followed by open surgical aortic segment replacement and interval oesophageal repair have been described.<sup>15</sup>

Successful management requires a high index of suspicion with prompt diagnosis and arrest of bleeding with subsequent stabilisation of the patient. Although rare, the diagnosis of AEF should be considered in a patient presenting with massive upper GI bleeding. Tuberculous disease should also be considered in patients from areas where tuberculosis is endemic.

The chest x-ray findings of possible infective changes were subtle and missed initially. The diagnosis of tuberculosis was thus only made at postmortem. The implication of making this diagnosis only at postmortem was that several healthcare workers were potentially exposed to miliary TB and had to consider post-exposure prophylaxis.

#### REFERENCES

1. Prokakis C, Charoulis N, Tselikos D, Koletsis EN, Apostolakis E, Dougenis D. Primary aorto-oesophageal fistula due to thoracic aortic aneurysm: successful surgical treatment. *Tex Heart Inst J* 2009;36:607-10.
2. Feezor RJ, Hess PJ, Lee WA. Endovascular treatment of a malignant aorto-oesophageal fistula. *J Vasc Surg* 2009;49:778.
3. Cheng LC, Chiu CSW. Foreign body-induced aorto-oesophageal fistula: A review of five cases and their management. *Hong Kong Med J* 2006;12:219-21.
4. Wiggins T, Chaudry MA, Vasas P, Bryant C, Hughes F, et al. Aorto-oesophageal fistula: an unusual complication of oesophageal biopsies. *BMJ Case Reports* 2011;10.1136/bcr.01.2011.3770.
5. Gavens E, Zaidi Z, Al-Jundi W, Kumar P. Aorto-oesophageal fistula after endovascular aortic aneurysm repair of a mycotic thoracic aneurysm. *Int J Vasc Med* 2011;2011:649592.
6. Hollander JE, Quick G. Aorto-oesophageal fistula: A comprehensive review of the literature. *Am J Med* 1991;91:279-87.
7. Michalopoulos A, Papadopoulos VN, Panidis S, Papavramidis TS, Chiotis A, Basdanis G. Cecal obstruction due to primary intestinal tuberculosis: a case series. *J Med Case Reports* 2011;5:28.
8. Mourra N, Marceau C, Pacanowski J, Turet E, Flejou JF. Massive haematemesis in an African male. *Gut* 2008;57:49.
9. Bavunoglu I, Ayan F, Karabicak I, Ledamo Y, Sayilgan C, Numan F, et al. Selective jejunal artery pseudoaneurysm embolization in a patient with massive gastrointestinal bleeding due to intestinal tuberculosis. *J Emerg Med* 2006;31:391-4.
10. Catinella FP, Kittle CF. Tuberculous esophagitis with aortic aneurysm fistula. *Ann Thorac Surg* 1988;45:87-8.
11. Lee OJ, Kim SH. Aorto-oesophageal fistula associated with tuberculous mediastinitis, mimicking esophageal Dieulafoy's disease. *J Korean Med Sci* 2002;17:266-9.
12. Flores J, Shiiya N, Kunihara T, Yoshimoto K, Yasuda K. Aorto-oesophageal fistula: Alternatives of treatment case report and literature review. *Ann Thorac Cardiovasc Surg* 2004;10:241-6.
13. Ferrero E, Viazzo A, Ferri M, Rocca R, Pecchio A, Piazza S, et al. Acute management of aorto-oesophageal fistula and tracheo-oesophageal fistula treated by thoracic endovascular aortic repair and esophageal endoprosthesis: a case misdiagnosed as esophageal cancer. *Ann Vasc Surg* 2011;25:1142.
14. Coselli JS, Crawford ES. Primary aorto-oesophageal fistula from aortic aneurysm: successful surgical treatment by use of omental pedicle graft. *J Vasc Surg* 1982;12:269-77.
15. Topel I, Stehr A, Steinbauer MG, Piso P, Schlitt HJ, Kasprzak PM. Surgical strategy in aorto-oesophageal fistulae: endovascular stentgrafts and in situ repair with cryopreserved homografts. *Ann Surg* 2007;246:853-9.

Yuyi Yeow,<sup>1</sup> MBBS, MRCS(Edin), Sau Shung Fong,<sup>1</sup> MBBS, MMED(Surgery), FRCS(Edin), Jaideep Raj Rao,<sup>1</sup> MBBS, FRCS(Edin), FAMS, Richard Sim,<sup>1</sup> MBBS, FRCS(Glasgow), FAMS

<sup>1</sup>Department of General Surgery, Tan Tock Seng Hospital, Singapore

Address for Correspondence: Dr Yuyi Yeow, Department of General Surgery, Tan Tock Seng Hospital, 11 Jalan Tan Tock Seng, Singapore 308433. Email: yeowyy@gmail.com